

Faculty



Michael U. Puderbach, MD

Research Interests

Morphological and functional lung imaging/post processing using Computed tomography (CT) and Magnetic resonance imaging (MRI)

- >> Short CV
- >> Projects
- >> Funding
- >> Team
- >> Selected Publications
- >> homepage of the respective institute/department

Short CV

Affiliation

Michael U. Puderbach
Assistant Professor of Radiology
Senior consultant, Diagnostic and Interventional Radiology

Thoraxklinik Heidelberg gGmbH at Ruprecht-Karls-University Heidelberg
Amalienstr. 5
69126 Heidelberg
Phone: +49 (0)6221 396-8061
Email: michael.puderbach@thoraxklinik-heidelberg.de
homepage: <http://www.thoraxklinik-heidelberg.de/index.php?id=48>

Curriculum Vitae:

- 1995 – 2002 Medical School
 Preclinical and clinical courses: University of Mainz, Germany
 Internship: University of Mainz, Germany; University of Virginia, USA
 Final Medical Examination: Medical Doctor
- 2002 – 2008 Residency in Radiology, DKFZ Heidelberg
- 2008 Board–Certification for Diagnostic Radiology
- 2006 – 2010 Head of the “Chest Imaging Group”, DKFZ Heidelberg
- 2008 – 2010 Head of the “Emmy Schmidt Group for clinical research”, DKFZ Heidelberg
- 2008 – 2010 Senior consultant, DKFZ Heidelberg
- 2010–
present Secretary of the “Heidelberg Thorax Imaging Platform” (HTIP), Heidelberg
- 2008 – 2010 Deputy acting Head of the Department of Radiology, German Cancer Research Center (DKFZ) Heidelberg
- 2010 – 2011 Senior consultant; Department of Diagnostic and Interventional Radiology, Thoraxklinik at the University of Heidelberg
- 2010 – 2012 Secretary of the “Heidelberg Thorax Imaging Platform” (HTIP), Heidelberg
- 2011 Postdoctoral Qualification as University Lecturer at the University of Heidelberg
 “Development of MRI of the Lung in Patients with Cystic Fibrosis”
- 2011 –
present Assistant Professor, senior consultant Diagnostic and Interventional Radiology with Nuclear Medicine, Thoraxklinik at Ruprecht–Karls–University Heidelberg
- 2012 –
present Executive board member “Heidelberg Thorax Imaging Platform” (HTIP), Heidelberg

Honors & Awards

- 2007 Poster award, European Congress of Radiology
- 2005 Stipend, Japanese/German Radiological Affiliation
- 2004 Poster award, European Congress of Radiology
- 2004 Poster award, German Society for Radio oncology
- 2004 Poster award, International Workshop on Pulmonary Functional Imaging
- 2004 Poster award, European Society of Thoracic Imaging
- 2001 Stipend, Robert Müller Society

Projects

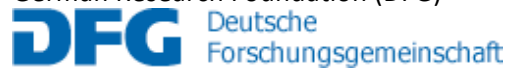
- Morphological and functional lung imaging using MRI (CF, COPD, BC, Fibrosis)
- CT lung imaging (CF, COPD, BC, Fibrosis)
- Image post processing of morphological and functional lung CT and MRI data

Funding

Federal Ministry for education and research (BMBF)



German Research Foundation (DFG)



Mukoviszidose e.V.



Selected Publications:

1. Biederer J, Mirsadraee S, Beer M, Molinari F, Hintze C, Bauman G, Both M, Van Beek EJ, Wild J, Puderbach M. MRI of the lung (3/3)-current applications and future perspectives. *Insights Imaging*. 2012 Aug;3(4):373-86.
2. Wielpütz MO, Eichinger M, Zhou Z, Leotta K, Hirtz S, Bartling SH, Semmler W, Kauczor HU, Puderbach M, Mall MA. In vivo monitoring of cystic fibrosis-like lung disease in mice by volumetric computed tomography. *Eur Respir J*. 2011 Nov;38(5):1060-70.
3. Eichinger M, Optazait DE, Kopp-Schneider A, Hintze C, Biederer J, Niemann A, Mall MA, Wielpütz MO, Kauczor HU, Puderbach M. Morphologic and functional scoring of cystic fibrosis lung disease using MRI. *Eur J Radiol*. 2011 Mar 21.
4. Bauman G, Puderbach M, Deimling M, Jellus V, Chefd'hotel C, Dinkel J, Hintze C, Kauczor HU, Schad LR. Non-contrast-enhanced perfusion and ventilation assessment of the human lung by means of fourier decomposition in proton MRI. *Magn Reson Med*. 2009 Sep;62(3):656-64.
5. Puderbach M, Eichinger M, Haeselbarth J, Ley S, Kopp-Schneider A, Tuengerthal S, Schmaehl A, Fink C, Plathow C, Wiebel M, Demirakca S, Müller FM, Kauczor HU. Assessment of morphological MRI for pulmonary changes in cystic fibrosis (CF) patients: comparison to thin-section CT and chest x-ray. *Invest Radiol*. 2007 Oct;42(10):715-25.